

Conservative treatment of shovel-shaped upper incisors and *dens invaginatus*: a case study

Maisa Oliveira Caliani Corral Morales¹

Luiz Evaristo Ricci Volpato²

Fabio Luis Miranda Pedro²

Cyntia Rodrigues de Araújo Estrela³

Álvaro Henrique Borges²

ABSTRACT

The purpose of this paper was to describe the conservative treatment adopted in one non-syndromic patient presenting with shovel-shaped upper incisors and *dens invaginatus*. A 13-year-old female patient sought treatment reporting pain in response to cold stimuli in the upper anterior teeth. Four upper incisors with shovel-shaped anatomical alterations in the palatal side of the crown were detected during intra-oral clinical examination; in addition, imaging exams revealed a type I *dens invaginatus* in tooth 22. There was no communication between the carious lesion and the pulp chamber, and a restorative treatment plan was developed. After 2 years of follow-up, the patient showed absence of pain, fistulas, swelling, or periodontal pockets. When faced with anomalous teeth, conservative procedures should be considered as a potential solution for restorative and endodontic treatment.

Keywords: Conservative Treatment, *Dens invaginatus*, Shovel-shaped Teeth, Tooth Abnormalities.

Tratamento conservador de incisivos superiores em forma de pá e *dens invaginatus*: um estudo de caso

RESUMO

O objetivo desse trabalho foi descrever o tratamento conservador adotado em um paciente não síndrômico apresentando incisivos em forma de pá (*shovel-shaped*) e *dens invaginatus*. Paciente de 13 anos de idade, do sexo feminino, procurou tratamento com queixa de dor em resposta a estímulos frios nos dentes superiores anteriores. Quatro incisivos superiores com alterações anatômicas em forma de pá na face palatal da coroa foram detectados durante o exame clínico intraoral; além disso, exames de imagens revelaram a presença de *dens invaginatus* tipo I no dente 22. Não havia comunicação entre a cárie e a câmara pulpar, e um plano de tratamento restaurador foi desenvolvido. Após 2 anos de seguimento, a paciente demonstrava ausência de dor, fistulas, edema ou bolsas periodontais. Ao se deparar com anomalias dentárias, procedimentos

1. Specialist in Pediatric Dentistry and a candidate at the Master's Program of Integrated Dentistry, University of Cuiabá, Cuiabá, MT, Brazil.

2. Professors at the Program of Integrated Dentistry, University of Cuiabá, Cuiabá, MT, Brazil.

3. PhD in Cellular and Molecular Biology from the Federal University of Goiás, GO, Brazil.

Corresponding Author: Álvaro Henrique Borges. Program of Integrated Dentistry, University of Cuiabá, Cuiabá, MT, Brazil. Tel.: +55-65-3363 1000. E-mail: ahborges@brturbo.com.br

conservadores devem ser considerados como uma potencial solução de tratamento restaurador e endodôntico.

Palavras-chave: Tratamento Conservador. *Dens invaginatus*. Dentes em Forma de Pá. Anormalidades Dentárias.

INTRODUCTION

Dental anomalies are defects caused by genetic disorders or environmental factors during tooth structure formation (1-3). Teeth begin to develop around the sixth week of intrauterine life, and the process continues through many stages (1). Even though developmental anomalies may occur at any stage, they will often manifest only later in life, when teeth are completely formed (2,3). Anomalies in shape (morphological anomalies) may involve only one tooth, a group of teeth, or even the complete dentition (4). The simultaneous presence of multiple anomalies may be related to specific syndromes, especially in patients with chromosomal alterations combined with multi-systemic alterations (2,5).

Dens invaginatus is a developmental anomaly resulting from invaginations in the external surface of the tooth crown prior to mineralization of the hard tissues (6). The etiology of the condition is still controversial and may be related to local delays in enamel formation, folding of the enamel organ, or external influences on the tooth bud (7). The teeth most commonly affected are the upper lateral incisors, followed by the upper central incisors (6). Mandibular teeth are rarely affected (8), and few cases have been reported involving the deciduous dentition (8). Cases of bilateral occurrence have been reported, and the exact homology remains to be investigated in cases where just one tooth is affected (6). Depending on the depth of enamel invaginations inside the tooth, anomalies may be classified as type I (the invagination ends as a blind sac and is limited to the coronal portion), type II (the invagination extends to the cemento-enamel junction [CEJ] but remains within the main canal), or type III (the invagination extends throughout the entire interior of the root canal and reaches the apical area of the tooth, giving rise to two or more foramina) (9).

Shovel-shaped incisors are anatomically characterized by a robust marginal ridge surrounding a deep lingual fossa (5). Although the etiology of shovel-shaped incisors has been shown to involve a genetic component (10), these teeth are considered to be anatomical variants rather than morphological defects (5). They differ considerably among distinct ethnic groups and are commonly found in Asians, Africans and Native Americans, but rarely among Europeans (10). The condition may affect 9% of the incisors (4% of the central and 5% of the lateral ones) (11).

Even though *dens invaginatus* and shovel-shaped incisors are rare anomalies, they may pose challenges to dental practitioners in terms of the restorative and endodontic treatment of the teeth affected (1). When deciding upon the most appropriate treatment, it is important to consider the degree of pulp involvement vs. biophysical characteristics of the tooth, symptoms reported, and pulp vitality test results (12).

The present study describes the conservative treatment adopted in a non-syndromic female patient presenting with shovel-shaped upper incisors and *dens invaginatus* in tooth 22.

CASE DESCRIPTION

A 13-year-old white female patient sought treatment at the Pediatric Dental Clinic of the Cuiabá School of Dentistry (Cuiabá, MT, Brazil), reporting pain in response to cold stimuli affecting the upper anterior teeth. Four upper incisors with shovel-shaped anatomical alterations in the palatal side of the crown were detected during intra-oral clinical examination, as well as carious lesions in teeth 12, 21, and 22 (Figure 1A). Pulp tests were performed in all anterior teeth using Endo-Frost (Roeko-Wilcos do Brasil, Rio de Janeiro, RJ, Brazil) and suggested the presence of vital pulp tissue. As a result, treatment plan consisted of eliminating the offending agent. Tooth 12 was restored using EvoluX composite resin (Dentsply™, Maillefer), whereas teeth 11 and 21 underwent four weekly sessions using Duraphat fluoride varnish (Colgate™, A. Nattermann & Cie. GmbH, Germany) (Figure 1F).

An open hollow area containing a cavity was found in tooth 22 during clinical examination (Figure 1B). After radiographic examination, the area was found to be as radiopaque as enamel. It extended from the cingulate area toward the root canal and was restricted to a small circle in the crown, corresponding to type I tooth invagination (Figure 2A). No communication was found between the carious lesion and the pulp chamber while inspecting the invaginated area (Figure 2B). Therefore, a restorative treatment plan was developed. Anesthesia consisted of infraorbital nerve block with palatal complementation. A rubber dam was placed, and decayed tissues were removed (Figure 1C). After gaining access to the invaginated area, the cavity was sealed with Vitremer® glass ionomer cement (3M® ESPE, St. Paul, MN, USA) (Figure 1D). A periapical radiograph was obtained to confirm sealing of the invagination (Figure 2C). Subsequently, the tooth was restored using EvoluX composite resin (Dentsply™, Maillefer). The rubber dam was then removed and occlusion was verified (Figure 1E). The patient was followed for 2 years. After this period, clinical (Figure 1F) and radiographic (Figure 2D) findings evidenced treatment success. The preservation of the pulp vitality was verified through the vitality test. An absence of pain, fistulas, swelling and periodontal pockets were also verified.

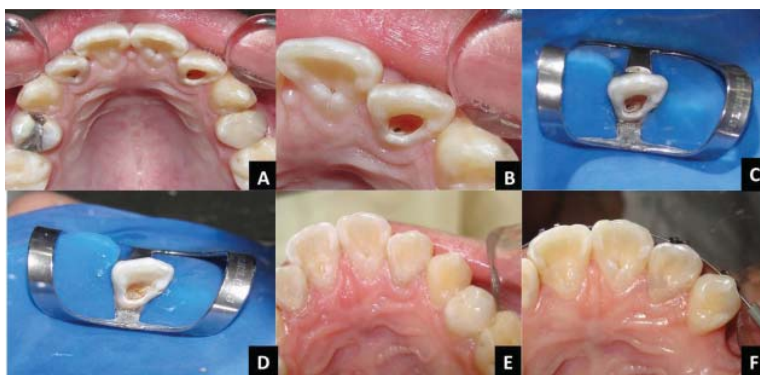

FIGURE 1 – A) Four upper incisors with shovel-shaped crowns and carious cavities in teeth 12, 21, and 22. B) Open hollow area containing a cavity found during clinical examination of tooth 22. C) Rubber dam placed and decayed tissues removed. D) Cavity sealed using glass-ionomer cement. E) Tooth restored using composite resin. F) Patient at 2 years' follow-up.

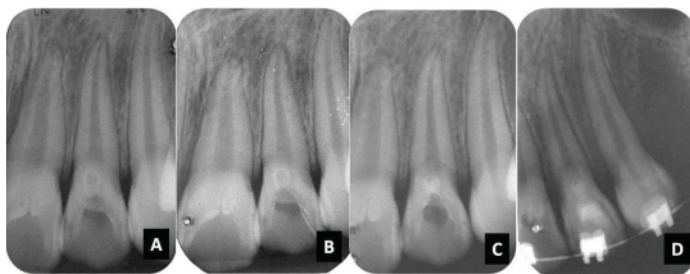


FIGURE 2 – A) Radiopaque area extending from the cingulate area toward the root canal and restricted to a small circle in the crown, corresponding to type I *dens invaginatus*. B) No communication between carious lesions and pulp chamber. C) Sealing of invagination. D) Radiograph obtained at 2 years' follow-up.

DISCUSSION

Anomalies occur as a consequence of genetic and environmental factors that interfere with the morphological differentiation of dental structures (2). The simultaneous presence of multiple anomalies may be related to specific syndromes, particularly in patients with chromosomal and multi-systemic alterations (2,5). However, there are also reports in the literature of patients without generalized abnormalities or a positive family history who are diagnosed with dental anomalies (9), as was the case with the patient here described.

Our patient presented with four shovel-shaped upper incisors and a type I *dens invaginatus* affecting an upper lateral incisor. To avoid the risk of root-pulp contamination, preventative and restorative treatment should be performed before the tooth is affected by dental caries (7). Treatment decisions should be based on an in-depth pre-operative evaluation of the gravity and complexity of the invagination (12,13).

Dens invaginatus is a developmental anomaly that most commonly affects the upper lateral incisors (6), and type I invagination is its most common manifestation (14). When the invagination does not connect with the root canal system, pulp vitality may be preserved (15). Under these circumstances, patient age, physical integrity, associated conditions, and the morphological characteristics of the anomaly will determine the best treatment approach (12). Conservative restoration procedures, surgical therapies, or tooth extraction may be used (15). In the present case study, pulp vitality tests were necessary to verify that the pulp was healthy (12,13). The presence of a carious lesion with no pulp involvement led to the decision of immediately sealing the invagination and restoring the tooth, so as to prevent the need for further pulp treatment.

Shovel-shaped incisors are regarded as an anatomical variation rather than as a morphological defect (5). Upper incisors are the teeth most commonly affected (16). Notwithstanding, due to difficulties with proper cleaning, these teeth may end up allowing the entry of microorganisms and irritants, increasing the susceptibility of the dental structure to tooth decay (15). Chronic irritation results in pulp necrosis and apical abscess, which should be prevented by sealing the cavity with sealant or restorative material and

maintaining good oral hygiene (16). In our case, the use of composite resin was indicated to perform the restoration. Moreover, rigorous, regular reviews are recommended to maintain a physical barrier and prevent pulp contamination (7). Long-term clinical and radiographic monitoring will determine the efficacy of the therapeutic approach adopted.

CONCLUSION

Based on the case presented, it is possible to conclude that conservative procedures should be considered as a potential solution for the restorative and endodontic treatment of anomalous teeth.

REFERENCES

1. Metgud S, Metgud R, Rani K. Management of a patient with a taurodont, single-rooted molars associated with multiple dental anomalies: a spiral computerized tomography evaluation. *Oral Surg Oral Med Oral Pathol Oral Radiol Endod.* 2009;108:e81-6.
2. Suprabha BS, Sumanth KN, Boaz K, George T. An unusual case of non-syndromic occurrence of multiple dental anomalies. *Indian J Dent Res.* 2009;20:385-7.
3. Marques-da-Silva B, Baratto-Filho F, Abuabara A, Moura P, Losso EM, Moro A. Multiple taurodontism: the challenge of endodontic treatment. *J Oral Sci.* 2010;52:653-8.
4. Robbins IM, Keene HJ. Multiple morphologic dental anomalies: report of a case. *Oral Surg Oral Med Oral Pathol.* 1964;17:683-90.
5. Lorena SC, Oliveira DT, Odell EW. Multiple dental anomalies in the maxillary incisor region. *J Oral Sci.* 2003;45:47-50.
6. Carvalho-Sousa B, Almeida-Gomes F, Gominho LF, Albuquerque DS. Endodontic treatment of a periradicular lesion on an invaginated type III mandibular lateral incisor. *Indian J Dent Res.* 2009;20:243-5.
7. Sathorn C, Parashos P. Contemporary treatment of class II dens invaginatus. *Int Endod J.* 2007; 40:308-16.
8. Mupparapu M, Singer SR. A review of dens invaginatus (dens in dente) in permanent and primary teeth: report of a case in a microdontic maxillary lateral incisor. *Quintessence Int.* 2006;37:125-9.
9. Oehlers FA. Dens invaginatus (dilated composite odontome). I. Variations of the invagination process and associated anterior crown forms. *Oral Surg Oral Med Oral Pathol.* 1957;10:1204-18.
10. Kimura R, Yamaguchi T, Takeda M, Kondo O, Toma T, Haneji K, Hanihara T, Matsukusa H, Kawamura S, Maki K, Osawa M, Ishida H, Oota H. A common variation in EDAR is a genetic determinant of shovel-shaped incisors. *Am J Hum Genet.* 2009;85:528-35.
11. Saini TS, Kharat DU, Mokeem S. Prevalence of shovel-shaped incisors in Saudi Arabian dental patients. *Oral Surg Oral Med Oral Pathol.* 1990;70:540-4.
12. Estrela C. *Endodontic science.* São Paulo: Artes Médicas; 2009. 1223p.
13. Kristoffersen Ø, Nag OH, Fristad I. Dens invaginatus and treatment options based on a classification system: report of a type II invagination. *Int Endod J.* 2008;41:702-9.

14. Hülsmann M. Dens invaginatus: aetiology, classification, prevalence, diagnosis, and treatment considerations. *Int Endod J.* 1997;30:79-90.
15. Kirzioğlu Z, Ceyhan D. The prevalence of anterior teeth with dens invaginatus in the western Mediterranean region of Turkey. *Int Endod J.* 2009;42:727-34.
16. Galindo-Moreno PA, Parra-Vázquez MJ, Sánchez-Fernández E, Avila-Ortiz GA. Maxillary cyst associated with an invaginated tooth: a case report and literature review. *Quintessence Int.* 2003;34:509-14.